

Fecal incontinence in older women: are levator ani defects a factor?

Christina Lewicky-Gaup, MD; Cynthia Brincat, MD; Aisha Yousuf, MD; Divya A. Patel, PhD; John O. L. Delancey, MD; Dee E. Fenner, MD

OBJECTIVE: We sought to compare pelvic floor structure and function between older women with and without fecal incontinence (FI) and young continent (YC) women.

STUDY DESIGN: YC ($n = 9$) and older continent (OC) ($n = 9$) women were compared to older women with FI (older incontinent [OI]) ($n = 8$). Patients underwent a pelvic organ prolapse quantification, measurement of levator ani (LA) force at rest and with maximum contraction, and magnetic resonance imaging. Displacement of structures and LA defects were determined on dynamic magnetic resonance imaging.

RESULTS: LA defects were more common in the OI vs the YC (75% vs 11%, $P = .01$) and OC (22%, $P = .14$) groups; women with FI were

more likely to have LA defects than women without (odds ratio, 14.0, 95% confidence interval, 1.8–106.5). OI women generated 27.0% and 30.1% less force during maximum contraction vs the OC ($P = .13$) and YC ($P = .04$) groups. During Kegel, OI absolute structural displacements were smaller than in the OC group ($P = .01$).

CONCLUSION: OI women commonly have LA defects, and cannot augment pelvic floor strength.

Key words: fecal incontinence, levator ani defects

Cite this article as: Lewicky-Gaup C, Brincat C, Yousuf A, et al. Fecal incontinence in older women: are levator ani defects a factor? *Am J Obstet Gynecol* 2010;202:491.e1-6.

With aging, the prevalence of fecal incontinence (FI) increases.^{1,2} FI is a debilitating condition^{3,4} and a common cause of institutionalization in the elderly,⁵ yet the mechanisms underlying FI are still not fully understood.⁶ Fecal continence is maintained by a complex sphincter system involving 3 anatomical elements: the smooth muscle internal anal sphincter, the striated external anal sphincter (EAS), and levator ani (LA) muscles. Failure of each of these elements has been implicated in the multifactorial etiology of FI, however, how much the failure of each these individual

components, especially the LA, contribute to FI has not been reported.

It is known that LA muscle defects are associated with pelvic organ prolapse (POP)⁷ and difficult vaginal delivery.⁸ In addition, Nichols et al⁹ found that anal incontinence was more common in women with pelvic floor disorders (including POP and/or urinary incontinence) than normal controls. However, the association of LA defects with FI is still unclear. The aims of this study were 2-fold. First, it was our objective to examine the relationship of LA muscle structure as it relates to FI in older women using dynamic magnetic resonance (MR) imaging (MRI). Second, we sought to examine changes in the function of the pelvic floor (specifically, force of LA contraction and movement of perineal structures with Kegel and Valsalva) that occur in older women with FI.

MATERIALS AND METHODS

We recruited 8 older women with weekly FI aged 63–85 years (older incontinent [OI]) as well as 9 young continent (YC) women aged 20–41 years and 9 older continent (OC) women aged 60–88 years (representing asymptomatic continent control groups) from February 2006 through October

2007. Due to funding limitations, young incontinent women were not recruited. Subjects were recruited through the university-based gynecology clinic and campus-wide advertisements. All were community dwelling. The study was approved by the university's institutional review board (#2005-0294).

As previously described,¹⁰ older women who reported loss of solid stool ≥ 1 /wk and had a Wexner score of > 8 were considered cases. Women who reported *only* incontinence of gas/flatus or reported the use of a pad or lifestyle alterations *without* reporting loss of solid stool were not included. Continent controls (both older and younger) had to have a Wexner score of < 4 . Exclusion criteria was as follows: previous gynecological surgery for pelvic floor disorders and prolapse, previous anal sphincter repair surgery, current treatment for cancer, chronic use of steroids, human immunodeficiency virus–positive status, sickle cell disease, irritable bowel syndrome (based on Rome III criteria), neurological conditions, uncontrolled diabetes, stroke, or Alzheimer disease. Women who had undergone hysterectomy were eligible if the indication for

From the Division of Gynecology, Department of Obstetrics and Gynecology, Pelvic Floor Research Group, University of Michigan, Ann Arbor, MI.

Presented at the 30th Annual Scientific Meeting of the American Urogynecologic Society, Hollywood, FL, Sept. 23–26, 2009.

Received July 6, 2009; revised Oct. 10, 2009; accepted Jan. 11, 2010.

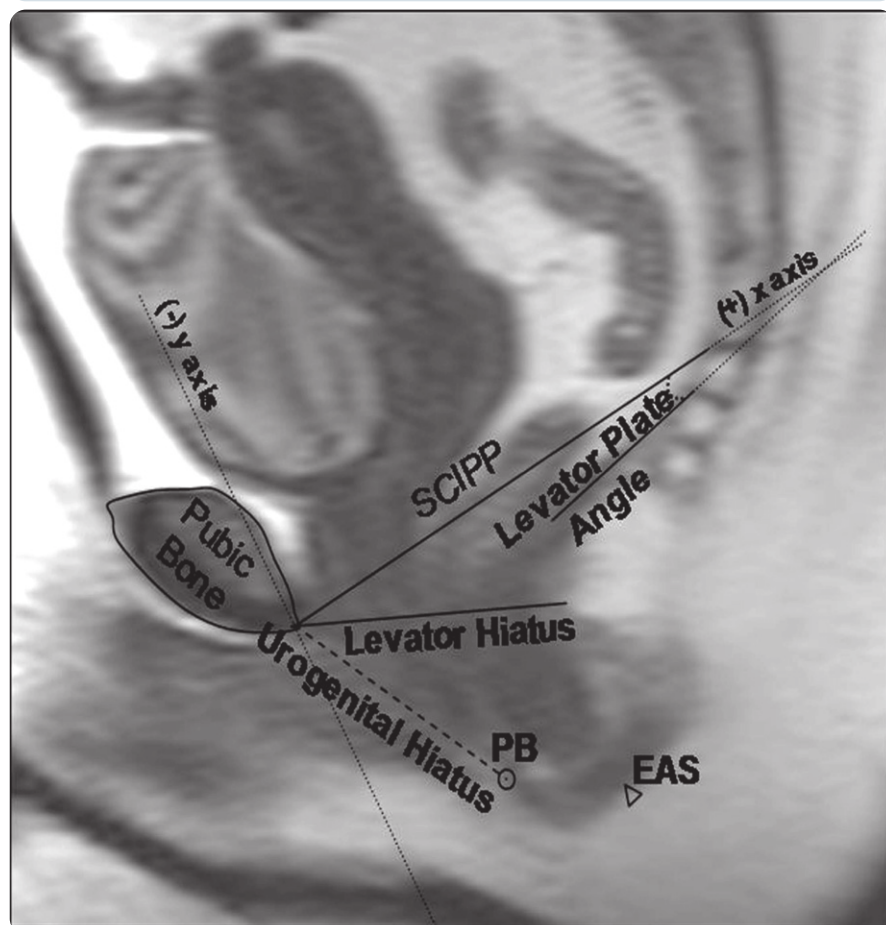
Reprints not available from the authors.

The authors gratefully acknowledge research support from the Claude A. Pepper Foundation Grant P30AG024824 for this project.

0002-9378/\$36.00

© 2010 Published by Mosby, Inc.
doi: 10.1016/j.ajog.2010.01.020

FIGURE 1
Midsagittal MRI of structures at rest



EAS, external anal sphincter; MRI, magnetic resonance imaging; PB, perineal body; SCIPP, sacrococcygeal-inferior pubic point (x-axis). Lewicky-Gaupp. FI in older women: are levator ani defects a factor? *Am J Obstet Gynecol* 2010.

the surgery was not prolapse and occurred at least 1 year before enrollment.

To assess vaginal and uterine support, all women were examined using POP quantification (POPQ) measurements in the semirecumbent position at a 45-degree angle. To assess LA muscle function, an instrumented speculum examination was performed to measure LA muscle force with maximal contraction (F_{LAC}) and at rest as previously described in our group's work.¹¹

Women also underwent transrectal ultrasound as reported in our previous study.¹⁰ All women also underwent dynamic, supine MRI of the pelvic floor. Images were taken in the axial, saggital, and coronal planes using a fast spin proton density technique. Scans were performed on a 1.5-T superconducting

magnet (Signa; General Electric Medical Systems, Milwaukee, WI). Slice thickness was 4 mm, with a gap of 1 mm, yielding 5-mm image spacing. A total of 20 mL of ultrasound gel was added to the vagina to better delimit its location and boundaries.

Using an identification and grading system for LA defects (encompassing both the pubovisceral and puborectal portions of the muscle) previously described by our group,^{8,12} muscle defects were identified on static, axial images in all 3 groups. Examiners were blinded to the age and continence status of all of the subjects.

On static, midsagittal MRI at rest, maximum Kegel, and maximum Valsalva, a sacrococcygeal-inferior pubic point (SCIPP) line (x-axis) and perpen-

dicular y-axis were drawn. Using these axes as references, measurements of levator and urogenital hiatus diameters were made in all 3 groups and compared. The angle of the levator plate was measured relative to the SCIPP line as well. When the levator plate was parallel to SCIPP line, the angle was considered zero. When the angle was above the parallel in a clockwise direction, it was considered negative. When it was below the parallel in a counterclockwise direction, the angle was considered positive. Similarly, on dynamic images, locations of the perineal body (PB) and EAS were determined as x and y coordinates in centimeters relative to these axes, again at rest, maximum Kegel, and maximum Valsalva (Figure 1). Using these x and y coordinates, displacements of the PB and EAS from rest to maximum Kegel as well as from rest to maximum Valsalva in each individual were calculated. All measurements were made using software (Image J 1.4j; National Institutes of Health, Bethesda, MD).¹³

All statistical analyses were completed using software (SPSS, Version 16.0; SPSS, Inc, Chicago, IL). Bivariate relationships were explored among the OI, OC, and YC group POPQ points and MRI measures using analysis of variance. Additional pairwise comparisons with Student *t* tests were made when a significant difference between the groups was detected with analysis of variance. To determine whether LA defects were associated with continence status, the OC and YC groups were combined and compared to the OI group. Logistic regression analyses with and without adjustment for EAS defects were conducted to determine associations between LA defects in women with FI (OI) and those without (OC + YC) as well. An alpha of ≤ 0.05 was used for significance in all tests.

RESULTS

The demographics of the OI, OC, and YC groups are shown in Table 1. No significant differences were observed between the OI and OC groups. The OI group was significantly older than the YC group and had more vaginal and for-

TABLE 1
Demographics among 3 cohorts

Variable	OI (n = 8)	OC (n = 9)	OI vs OC P value	YC (n = 9)	OI vs YC P value	OC vs YC P value
Mean age, y (SD)	71.6 (7.5)	71.6 (7.5)	.8	28.7 (7.3)	< .001	< .001
Mean BMI, kg/m ² (SD)	27.6 (4.2)	25.4 (4.3)	.3	27.2 (7.4)	.9	.5
Mean vaginal parity, n (SD)	2.6 (1.2)	2.8 (1.7)	.8	0.2 (0.4)	< .001	< .001
Mean forceps-assisted deliveries, n (SD)	1.0 (1.1)	0.6 (1.0)	.4	0	< .001	.1
Mean cesarean sections, n (SD)	0.1 (0.4)	0	.4	0.1 (0.3)	.9	.3

BMI, body mass index; OC, older continent; OI, older incontinent; YC, young continent.

Lewicky-Gaupp. FI in older women: are levator ani defects a factor? *Am J Obstet Gynecol* 2010.

ceps-assisted deliveries. The OC group was also older and had more vaginal deliveries than the YC group. All 3 groups were similar with respect to number of bowel movements per week (OI = 9.9 ± 2.3, OC = 7.6 ± 1.2, YC = 8.3 ± 1.3; *P* = .34).

Differences in pelvic organ support on POPQ examination among the OI, OC, and YC groups are shown in Table 2. No significant differences in POPQ were seen between the 2 groups of older women (OI and OC). The OI group had less anterior vaginal wall support than YC group (points Aa and Ba); apical support (point D) was also diminished in the OI group compared to the YC group. Posterior support, genital hiatus, and PB measurements did not differ significantly between the OI and YC groups. Total vaginal length was slightly longer in the YC group compared to the OI group. Point D in the OC group

was less than the YC group as well. None of the women had prolapse outside of the hymen.

On MRI, LA defects were more common in the OI group of women than the OC or YC women, although these differences were only significant when the OI and YC women were compared (Table 3). As reported in our previous study, on transrectal ultrasound, 2 women in the OI group and 1 woman in the OC group had focal defects in the EAS.¹⁰ Overall, women with FI (OI) were more likely to have LA defects than women without FI (YC + OC) (odds ratio [OR], 14.0, 95% confidence interval [CI], 1.8–106.5). This association remained significant after adjustment for EAS defects (OR, 23.3, 95% CI, 2.0–267.6).

On instrumented speculum examination, LA muscle force at rest did not differ among the 3 groups, however, the OI

group generated 27.0% less F_{LAC} compared to the OC group and 30.1% less than the YC group (Table 3). Regardless of continence, women with LA defects had 25.9% less F_{LAC} (6.0 ± 2.3 N vs 8.1 ± 2.7 N) compared to those without a defect (*P* = .05).

During maximum Kegel, PB and EAS displacements were smaller in the OI group compared to the OC group (Figure 2); no differences were observed in displacement at maximum Valsalva among the 3 groups. At rest, the average PB location of the YC group was 1 cm closer to the pubic bone compared to the OC group and 1.6 cm closer compared to the OI group (*P* = .02 for both). Similarly, at rest, the EAS of the YC was located 1.2 cm closer to the pubic bone compared to the OC group and 1 cm closer compared to the OI group (*P* = .03 and *P* = .09, respectively). No differ-

TABLE 2
Pelvic organ prolapse quantification measurements among 3 cohorts

POPQ measure in cm, mean (SD)	OI (n = 8)	OC (n = 9)	OI vs OC P value	YC (n = 9)	OI vs YC P value	OC vs YC P value
Aa	-0.3 (2.0)	-1.4 (1.4)	.2	-2.4 (0.7)	.01	.1
Ba	-0.1 (2.6)	-1.5 (1.2)	.1	-2.4 (0.7)	.02	.1
C	-5.3 (4.1)	-7.1 (0.8)	.2	-7.6 (1.5)	.2	.5
D	-5.8 (4.3)	-7.9 (1.2)	.2	-9.6 (1.1)	.03	.01
Ap	-1.0 (2.4)	-1.6 (1.5)	.5	-2.3 (0.9)	.1	.3
Bp	-1.6 (1.0)	-1.6 (1.5)	.9	-2.3 (0.9)	.1	.3
GH	3.7 (1.8)	2.6 (0.7)	.1	2.4 (0.5)	.1	.5
PB	3.0 (1.8)	4.1 (1.7)	.9	3.5 (0.9)	.2	.2
TVL	9.3 (1.0)	9.4 (1.4)	.8	10.3 (0.9)	.04	.2

GH, genital hiatus; OC, older continent; OI, older incontinent; PB, perineal body; POPQ, pelvic organ prolapse quantification; TVL, total vaginal length; YC, young continent.

Lewicky-Gaupp. FI in older women: are levator ani defects a factor? *Am J Obstet Gynecol* 2010.

TABLE 3
Levator ani defect status and force generated

Variable	OI (n = 8)	OC (n = 9)	OI vs OC P value	YC (n = 9)	OI vs YC P value	OC vs YC P value
Any levator ani defect, % (n)	75.0 (6)	22.2 (2)	.14	11.0 (1)	.01	1.0
Levator ani force ^a						
F _{LAR}	4.2 (1.0)	4.1 (0.6)	.9	4.7 (0.9)	.4	.2
F _{LAC}	5.8 (2.4)	8.0 (3.2)	.1	8.3 (1.8)	.04	.83

F_{LAC}, levator ani muscle force maximal contraction; F_{LAR}, levator ani muscle force at rest; OC, older continent; OI, older incontinent; YC, young continent.

^a Values reported as means (SD).

Lewicky-Gaup. FI in older women: are levator ani defects a factor? *Am J Obstet Gynecol* 2010.

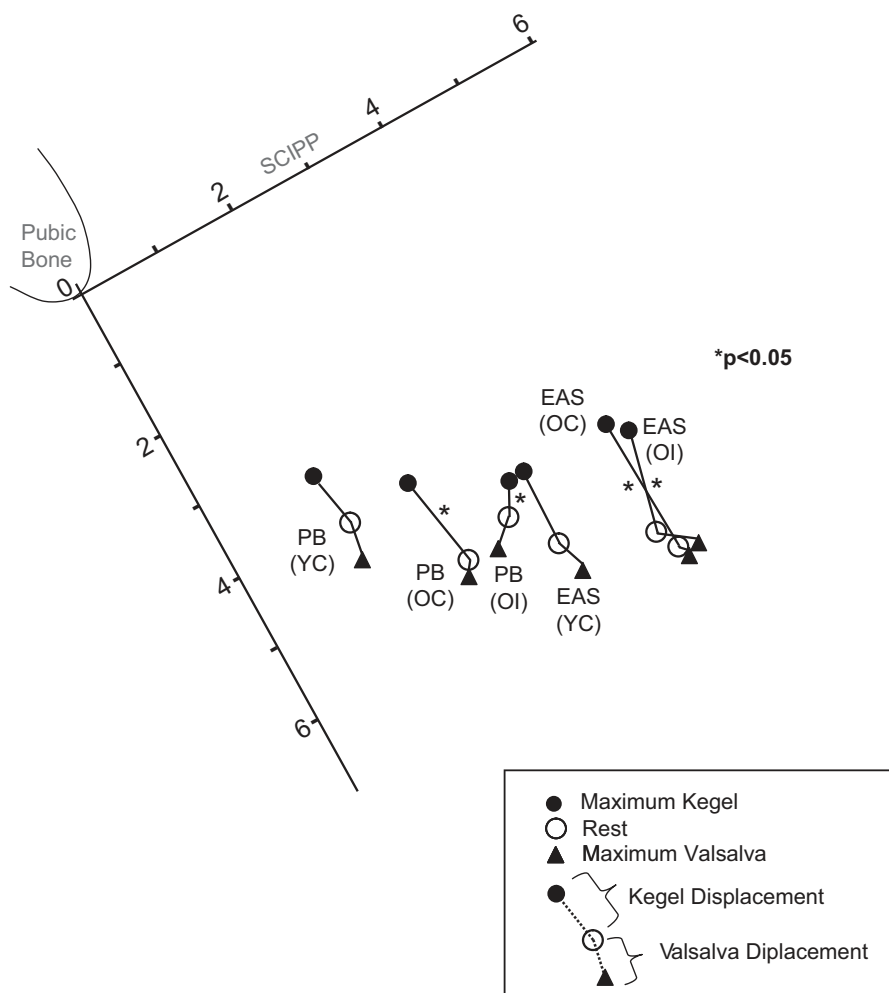
ences were seen between the 2 groups of older women (Figure 2).

Levator and urogenital hiatuses were significantly larger at rest, Kegel, and

maximum Valsalva in both groups of older women compared to the younger women (Table 4); no significant differences were seen in hiatus measurements

between the OI and OC groups. Similarly, the OI and OC groups had less vertically oriented levator plate angles with Kegel.

FIGURE 2
Location and displacement of PB and EAS



EAS, external anal sphincter; OC, older continent; OI, older incontinent; PB, perineal body; SCIIPP, sacrococcygeal-inferior pubic point; YC, young continent.

Lewicky-Gaup. FI in older women: are levator ani defects a factor? *Am J Obstet Gynecol* 2010.

COMMENT

In this study, we found that LA defects are significantly more common in FI older women and are strongly associated with FI, even when adjusting for defects in the EAS. Older women with FI are also unable to augment their pelvic floor strength, as shown by both direct measurement of decreased LA contractile force on instrumented speculum examination and indirect measurement of inability of elevate perineal structures on MRI. These findings suggest the importance of the levator muscles in maintaining fecal continence in this population of women.

The association of LA defects and EAS defects has been studied in postpartum women and in women with POP, but not in a group of OI women. Obstetrical observations have shown that sphincter lacerations and levator defects tend to occur together. For example, Kearney et al⁸ reported an increased OR of LA defect if a sphincter laceration was also present (OR, 8.1, 95% CI, 3.3–19.5) at first vaginal birth. Similarly, LA defects have been documented on MRI in some middle-aged women with FI and not in others.^{14,15} For example, in a study of 105 women with FI and a mean age of 57 ± 13 years, Terra et al¹⁴ showed that >30% of women had LA muscle defects, however, >80% of the defects were not isolated; they were associated with sphincter lacerations. On the other hand, in another study that compared 34 patients

TABLE 4
Magnetic resonance imaging anatomic differences among 3 cohorts of women

Variable	OI (n = 8)	OC (n = 9)	OI vs OC P value	YC (n = 9)	OI vs YC P value	OC vs YC P value
Mean levator hiatus, cm (SD)						
Rest	6.7 (1.0)	6.5 (1.0)	.80	5.5 (1.0)	.03	.05
Kegel	6.3 (1.0)	5.6 (0.7)	.14	4.5 (0.8)	.002	.01
Valsalva	7.0 (1.2)	6.9 (1.4)	.83	5.6 (1.0)	.03	.05
Mean urogenital hiatus, cm (SD)						
Rest	5.7 (1.2)	5.8 (1.0)	.87	4.4 (1.3)	.05	.02
Kegel	5.5 (1.2)	4.7 (0.8)	.15	3.6 (1.0)	.004	.02
Valsalva	6.1 (1.3)	6.0 (1.2)	.82	5.0 (1.3)	.002	.11
Mean levator plate angle, degrees (SD)						
Rest	10.9 (12.2)	11.0 (9.2)	1.00	-3.2 (20.2)	.12	.10
Kegel	3.4 (16.4)	-6.1 (6.6)	.16	-16.1 (10.6)	.02	.04
Valsalva	17.1 (14.6)	18.5 (14.5)	.85	12.1 (22.2)	.02	.50

OC, older continent; OI, older incontinent; YC, young continent.

Lewicky-Gaup. FI in older women: are levator ani defects a factor? *Am J Obstet Gynecol* 2010.

(mean age 57 ± 11.7 years) with anal incontinence on “most or every day” to 114 women reporting incontinence “never or on occasion,” there were no differences in LA defect status between the 2 groups.¹⁵ The majority of women in our study did not have sphincter lacerations, and the association of LA defects with FI persisted even when adjusting for the small number of sphincter defects that were present in this cohort. These findings emphasize likely differences in the mechanism of FI in younger and older women; while sphincter integrity is extremely important for continence in younger women, our findings would suggest that in older women, both sphincter and LA competence is crucial in maintaining fecal continence.

In this study, OI women exhibited impaired LA function. The 2 groups of older women, however, did not differ from one another in force generated, which is similar to our previous work where older age was not associated with an overall decrease in pelvic floor strength in a cohort of nulliparous women.¹⁶ Evaluating voluntary muscle function is difficult (as it is often measured by numerous, differing techniques) and relies on the effort of the patient. Therefore, it is not surprising that studies show conflicting data regarding pelvic floor

strength in women with FI. In a subanalysis of women with POP, Morgan et al¹⁵ showed no differences in LA augmentation force between women with and without FI. However, Fernandez-Fraga et al¹⁷ did find an association between pelvic floor function and FI severity. Women with FI and impaired LA function not only had more severe FI, but also did not respond as well to biofeedback therapy; this study, however, utilized a perineal dynamometer, which relies on an intrarectal balloon, to measure levator contraction. The authors did show distinction between levator and sphincter function; it is possible that their findings were still confounded by the sphincter itself.

The impaired LA function found in our study is further demonstrated by the inability of older women with FI to elevate pelvic structures on MRI with contraction. These findings are similar to those of Bharucha et al¹⁸ who found that one third of the patients studied with FI had reduced upward anorectal motion during squeeze on MR. Their findings, like others,¹⁹ however, were in a group of younger women (mean age 61.2 ± 14.4 years); of these women, 50% also carried a diagnosis of diarrhea-predominant irritable bowel syndrome. Similarly, Law et al²⁰ showed diminished elevation of

the anorectal junction in multiparous women, however, their findings focused on a group of women with symptomatic stress urinary incontinence rather than FI. Our study extends these findings in a population of older women without other functional bowel disorders, thus eliminating many confounders present in the current literature.

Levator and urogenital hiatus measurements on MRI were larger and levator plate angles more vertically oriented in older women, irrespective of continence status, compared to younger women. It is known that larger levator hiatus measurements and more caudal levator plate angles on MRI are associated with POP.^{21,22} However, studies looking at hiatal measurement changes with aging in women without prolapse are sparse. In our study, FI was not associated with changes in hiatus or levator plate measurements. This is inconsistent with other studies that have shown larger hiatal measurements in women with combined FI and urinary incontinence²³ when compared to asymptomatic controls. In our population of older women without clinical evidence of POP, our findings that size of hiatus was associated only with age and not continence status suggest that hiatal relaxation may be related to compromise of support struc-

tures other than the LA such as connective tissue. These findings also suggest that hiatal size, while important in the pathophysiology of POP, does not necessarily impact bowel function or control.

Several factors should be taken into account when interpreting the results of this study. First, due to our small sample size, our multivariable analysis was somewhat limited. Because sphincter lacerations and LA defects are interrelated, further analyses using larger sample sizes are needed to clarify the role of levator defects in the pathophysiology and mechanism of FI in the elderly. The majority of our OI women were Caucasian, and a more diverse cohort would be more representative of community-dwelling women. Also, we did not recruit a young group of women with FI which, in the future, will add breadth to the analysis.

In summary, the results of our study suggest an important role of the LA muscles in maintaining the fecal continence mechanism in elderly women. These findings support treatment modalities, such as pelvic floor exercises and muscle stimulation that target the LA muscles, for FI in populations of older women. In the future, it will be important to consider preventative strategies that decrease the risk of LA injury in younger women thereby potentially decreasing the incidence of FI as these women age. ■

REFERENCES

- Boreham MK, Richter HE, Kenton KS, et al. Anal incontinence in women presenting for gynecologic care: prevalence, risk factors, and impact upon quality of life. *Am J Obstet Gynecol* 2005;192:1637-42.
- Melville JL, Fan MY, Newton K, Fenner D. Fecal incontinence in US women: a population-based study. *Am J Obstet Gynecol* 2005;193:2071-6.
- Perry S, Shaw C, McGrother C, et al. Prevalence of fecal incontinence in adults aged 40 years or more living in the community. *Gut* 2002;50:480-4.
- Nelson RL. Epidemiology of fecal incontinence. *Gastroenterology* 2004;126(Suppl):S3-7.
- Specht JK. Nine myths of incontinence in older adults: both clinicians and the over-65 set need to know more. *Am J Nurs* 2005;105:58-68.
- Rao SS. Pathophysiology of adult fecal incontinence. *Gastroenterology* 2004;126(Suppl):S14-22.
- DeLancey JOL, Morgan DM, Fenner DE, et al. Comparison of levator ani muscle defects and function in women with and without pelvic organ prolapse. *Obstet Gynecol* 2007;109:295.
- Kearney R, Miller JM, Ashton-Miller JA, DeLancey JO. Obstetric factors associated with levator ani muscle injury after vaginal birth. *Obstet Gynecol* 2006;107:144-9.
- Nichols CM, Ramakrishnan V, Gill EJ, Hurt WG. Anal incontinence in women with and those without pelvic floor disorders. *Obstet Gynecol* 2005;106:1266-71.
- Lewicky-Gaupp C, Hamilton Q, Ashton-Miller J, Huebner M, DeLancey JO, Fenner DE. Anal sphincter structure and function relationships in aging and fecal incontinence. *Am J Obstet Gynecol* 2009;200:559e1-5.
- Sampsel C, Miller J, Mims B, Delancey J, Ashton-Miller J, Antonakos C. Effect of pelvic muscle exercise on transient incontinence during pregnancy and after birth. *Obstet Gynecol* 1998;91:406-12.
- Morgan DM, Umek W, Stein T, Hsu Y, Guire K, DeLancey JO. Interrater reliability of assessing levator ani muscle defects with magnetic resonance images. *Int Urogynecol J Pelvic Floor Dysfunct* 2007;18:773-8.
- Rasband WS. Image J, US National Institutes of Health, Bethesda, MD 1997-2008. Available at: <http://rsb.info.nih.gov/ij/>. Accessed July 1, 2009.
- Terra MP, Beets-Tan RG, Vervoorn I, et al. Pelvic floor muscle lesions at endoanal MR imaging in female patients with fecal incontinence. *Eur Radiol* 2008;18:1892-901.
- Morgan DM, DeLancey JO, Guire KE, Fenner DE. Symptoms of anal incontinence and difficult defecation among women with prolapse and a matched control cohort. *Am J Obstet Gynecol* 2007;197:509.e1-6.
- Trowbridge ER, Wei JT, Fenner DE, Ashton-Miller JA, Delancey JO. Effects of aging on lower urinary tract and pelvic floor function in nulliparous women. *Obstet Gynecol* 2007;109:715-20.
- Fernandez-Fraga X, Azpiroz F, Malagelada JR. Significance of pelvic floor muscles in anal incontinence. *Gastroenterology* 2002;123:1441-50.
- Bharucha AE, Fletcher JG, Harper CM, et al. Relationship between symptoms and disordered continence mechanisms in women with idiopathic fecal incontinence. *Gut* 2005;54:546-55.
- El Sayed RF, El Mashed S, Farag A, Morsy MM, Abdel Azim MS. Pelvic floor dysfunction: Assessment with combined analysis of static and dynamic MR imaging findings. *Radiology* 2008;248:518-30.
- Law PA, Danin JC, Lamb GM, Regan L, Darzi A, Gedroyc WM. Dynamic imaging of the pelvic floor using an open-configuration magnetic resonance scanner. *J Magn Reson Imaging* 2001;13:923-9.
- Hsu Y, Summers A, Hussain HK, Guire KE, Delancey JO. Levator plate angle in women with pelvic organ prolapse compared to women with normal support using dynamic MR imaging. *Am J Obstet Gynecol* 2006;194:1427-33.
- Ansquer Y, Fernandez P, Chapron C, et al. Static and dynamic MRI features of the levator ani and correlation with severity of genital prolapse. *Acta Obstet Gynecol Scand* 2006;85:1468-75.
- Eguare EI, Neary P, Crosbie J, et al. Dynamic magnetic resonance imaging of the pelvic floor in patients with idiopathic combined fecal and urinary incontinence. *J Gastrointest Surg* 2004;8:73-82.